

Toward Laryngeal Tumors Detection and Medical Images Segmentation Techniques

G. Dagnino, L.S. Mattos, and D.G. Caldwell

Advanced Robotics Dept., Istituto Italiano di Tecnologia, Genoa, Italy

- **Introduction**
 - Objective assessment of tumors margins
- **Pre-Operative Tumor Imaging**
 - State of the art of Larynx Imaging
- **Segmentation Algorithms**
 - Head and Neck applications
- **Real-Time Tumor Imaging**
 - Optical Imaging
 - Narrow-Band Imaging
 - Color-Coded Surgery
- **Conclusion and Future Works**

- Head and neck cancer is a major cause of morbidity and mortality [Szeto C. 2011];
- By leaving positive margins, the risk of local recurrence increases from 32% to 80% [Hughes O. R. 2010];
- Healthy tissue must be preserved (vocal and swallowing functions);
- Distinguish between healthy mucosa, dysplasia, and invasive carcinoma;



- **PRE-OPERATIVE IMAGING:** primary tumor definition (i.e. MRI, CT)
+
- **REAL-TIME IMAGING:** “translate” these images to the operation field
+
- **SEGMENTATION ALGORITHMS:** objectively assess tumor margins

LARYNX – Radiological Imaging

CT and MRI are the golden standard for pre-therapeutic staging of a head and neck malignancy.

<i>CT</i>	<i>MRI</i>
<ul style="list-style-type: none"> • Wide available; relative low cost • <u>Short examination time; less image degradation</u> caused by swallowing and respiration • <u>Superior bone detail</u> • Low soft tissue contrast resolution • <u>Radiation exposure</u> • Severe image degradation by dental fillings or other metallic objects • Preferred for evaluating laryngeal, hypopharyngeal cancer and oral cavity, oropharyngeal cancer • High quality multiplanar imaging • Easy extension into upper thoracic cavity or intracranial cavity • Needed administration of iodinated contrast agent 	<ul style="list-style-type: none"> • Lower availability; higher costs • <u>Long acquisition time; sensible to motion artifacts</u> • Lower bone detail • <u>Superior soft tissue resolution</u> • <u>Absence of radiation exposure</u> • Image quality not or less hampered by dental fillings • Preferred imaging for rarer head and neck malignancies (i.e. nasopharyngeal, sinonasal cancer)

Data from Hermans R. 2012

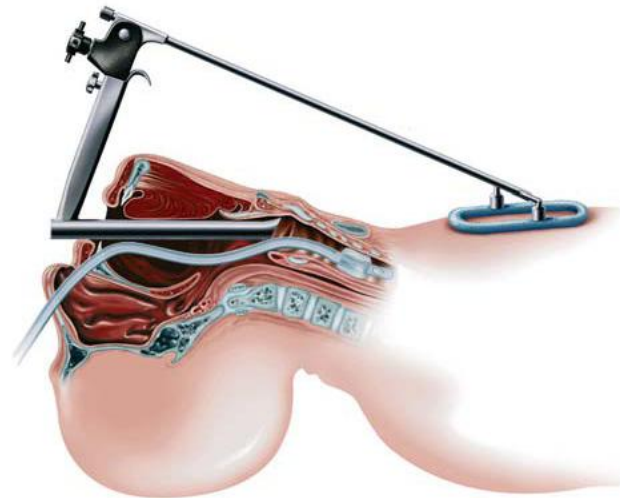
Accurate pretreatment record coupling information from radiological imaging and operative endoscopy.

LARYNX – Operative Endoscopy

- Hopkins rod telescope (70° or 90°) → Larynx (i.e. vocal folds function);
- Flexible nasendoscope → Postnasal space, pharynx, larynx;
- Direct Laryngoscopy → Mucosal lesion of larynx and pharynx;
- Operating Microscope (0°, 30°, 70°, and 120° telescopes) → Larynx lesions;



Image from Hermans R. 2012



Thresholding

- intensity value which separates the desired classes
- often used as initial step in a sequence of image processing operations

Region Growing

- extracting a region of the image that is connected based on predefined criteria
- requires a seed point selected by the operator

Classifiers

- pattern recognition techniques, requiring training data as references
- *maximum likelihood, Bayes, k-nearest-neighbor, Parzen window*

Clustering

- same function as classifiers without the use of training data
- iterate between segmenting and characterizing the properties of each class

Markov Random Field Modeling

- statistical model which can be used within segmentation methods
- often incorporated into clustering segmentation (maximizing the probability)

Neural Networks

- the most widely applied use in medical imaging is as a classifier
- weights determined using training data; the network is used to segment new data

Deformable Models

- delineate region boundaries using closed parametric curves or surfaces that deform under the influence of internal and external forces

Atlas Guided Approaches

- the atlas is generated by compiling information on the anatomy
- this atlas is then used as a reference for segmenting new images

Zaidi et al. Key comparative methods for PET image segmentation in NPC. Few works in literature about the application of segmentation algorithms as classification or regression for general MR images based on machine learning to head and neck lesions. Guiding principle by which all segmentations automatically generated from clustering-based segmentation (FCBS) and the spatial wavelet-based algorithm (SWBA). MRVE = mean relative volume errors;

<i>Authors</i>	<i>Target Lesion</i>	<i>Imaging Method</i>	<i>Algorithm Used</i>	<i>Results</i>
• Zhou et al. 2006	NPC	MRI	SVM	PM = 79±7%
• Ritthipravat et al. 2010	NPC	CT	Region Growing	PM = 85.03% PM* = 29.26%
• Zaidi et al. 2012	PSCC	PET	Thresholding (5) Active Contour SEM FCBS SWBA	MRVE = 100-400% MRVE = 27.20% MRVE = -31.88% MRVE = 35.58% MRVE = -5.94%
• Ingle and Kwon 2009	Whole Larynx	MRI	SVM k-means	OAM = 93% OAM = 94%

The introduction of real-time imaging technologies into the operating room has the potential of traversing the gap between radiology and surgery, resulting in intra-operative image-guided surgery.

Currently in routine use

- Optical Imaging Techniques:
 - Autofluorescence
 - Contact Endoscopy
- Narrow-Band Imaging

To be validated for Larynx

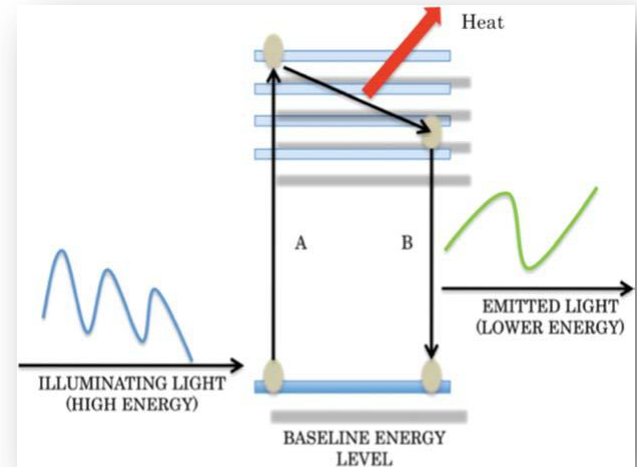
- Optical Imaging Techniques:
 - Confocal Endomicroscopy
- Color-Coded Surgery

Autofluorescence Endoscopy

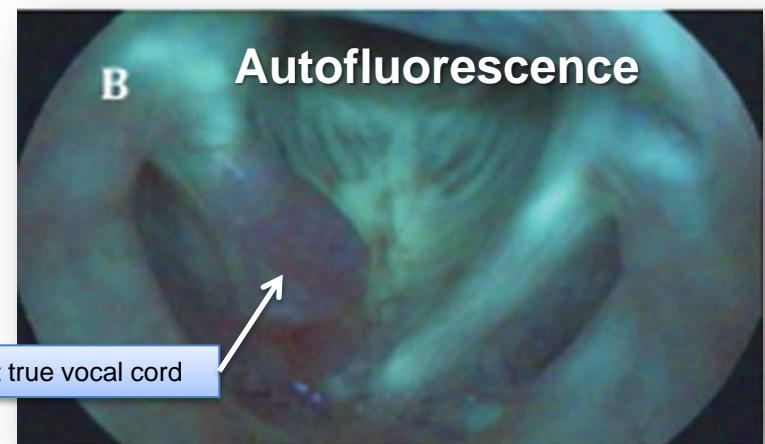

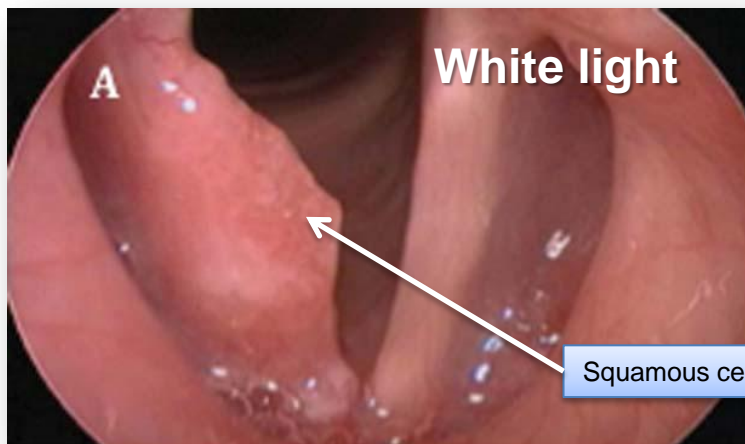
Autofluorescence is a property of few molecules, called fluorophores, which are present at different concentrations in healthy and neoplastic laryngeal mucosa.

Limitations:

- the light does not penetrate the diseased epithelium;
- scar tissue, necrosis, and inflammation can unpredictably alter mucosal fluorescence.



Figures from Hughes O. R. 2010



Squamous cell carcinoma of the right true vocal cord

Contact Endoscopy

- Cellular detail in vivo (methylene blue (MB) is applied to stain nucleic acids);
- Magnifying endoscope placed in direct contact with the mucosal surface;
- Images at 60x or 150x magnification;
- Neoplastic cells and blood vessels (from angiogenic processes) are stained by MB.
- Histological interpretations in vivo.

Applications [Szeto C. 2011]:

- Mucosal lesions:
 - dysplasia, hyperplasia, carcinoma, papilloma,...
- Specificity = 81-100%;
- Sensitivity = 79-100% ;
- Accuracy = 88-94%

Limitation:

- Cannot give clear images of cells beyond the most superficial layers of the epithelium.

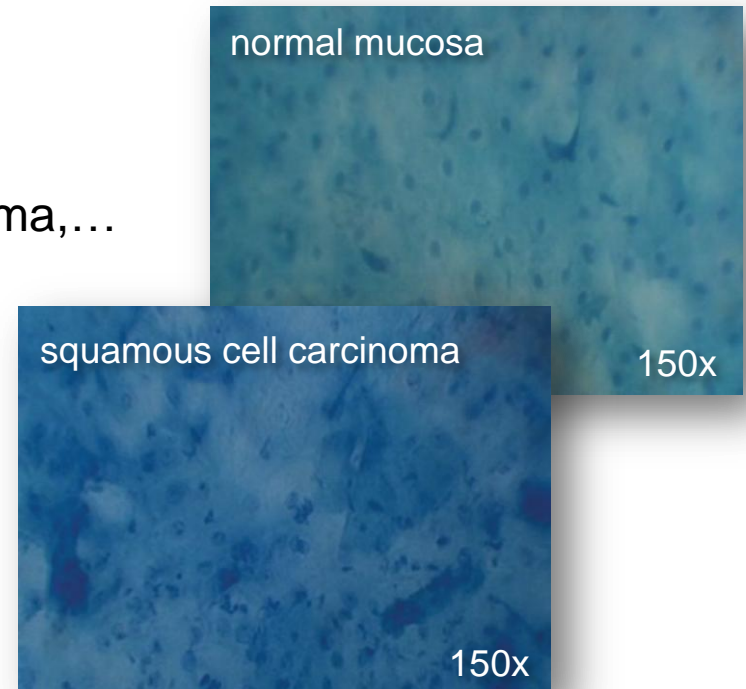
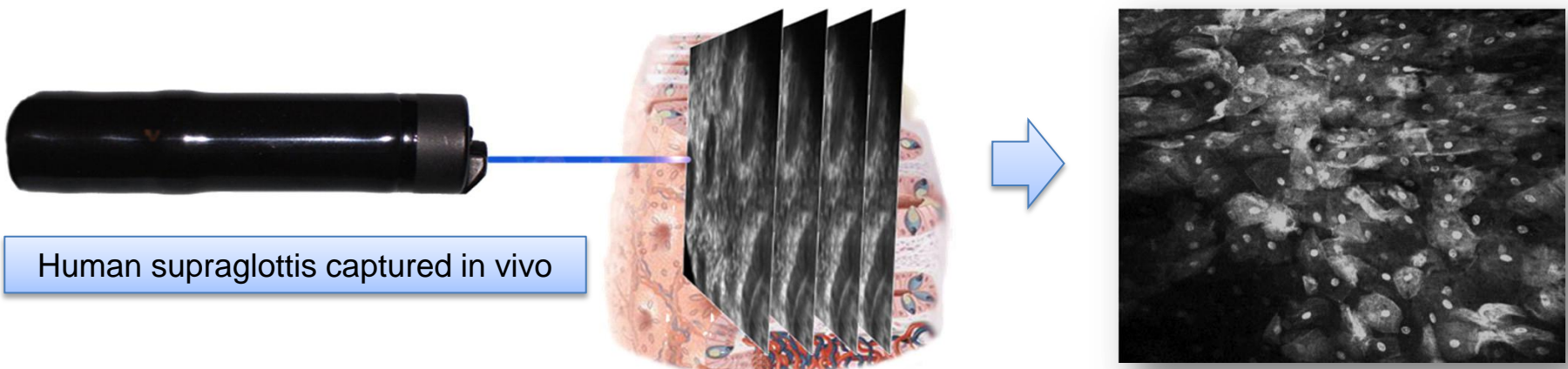


Figure from Szeto C. 2011

Confocal Endomicroscopy

- Allows tumors to be examined in 3D in vivo;
- Sufficient magnification to see histologic detail;
- Moving the focal plane through the tissue:
 - can see cells at different depths;
 - no lose image resolution;
 - “virtual biopsy” vs “real biopsy” (i.e. vocal cord permanent damage)
- Acriflavine hydrochloride stains cell nuclei;
- Gastrointestinal tract application*: reduced number of colon biopsies (-50%);
- Formal trials of confocal endomicroscopy in the larynx are awaited



Human supraglottis captured in vivo

Figure from Goetz M. 2010

Figures from Hughes O. R. 2010

Narrow-Band Imaging (NBI) (1)

- Depth of light penetration increases with wavelength;
- Tissue is illuminated with light centred around 415 nm (blue) and 540 nm (green), which are both absorbed by haemoglobin more strongly than by other tissue;
- The blue light enhances the superficial capillary network;
- The green light enhances the visibility of deeper vessels.

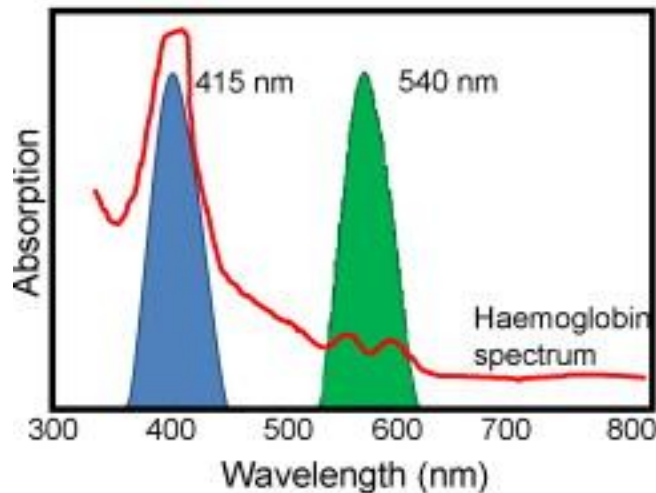
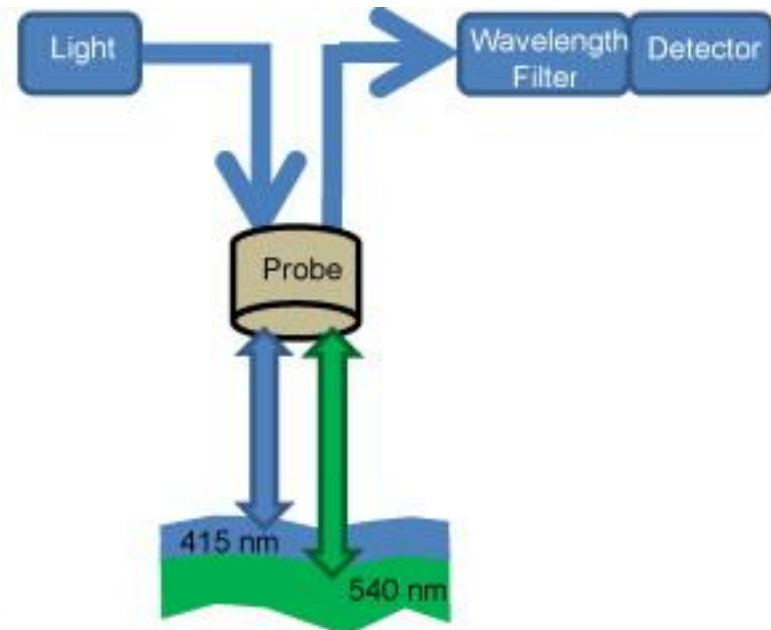
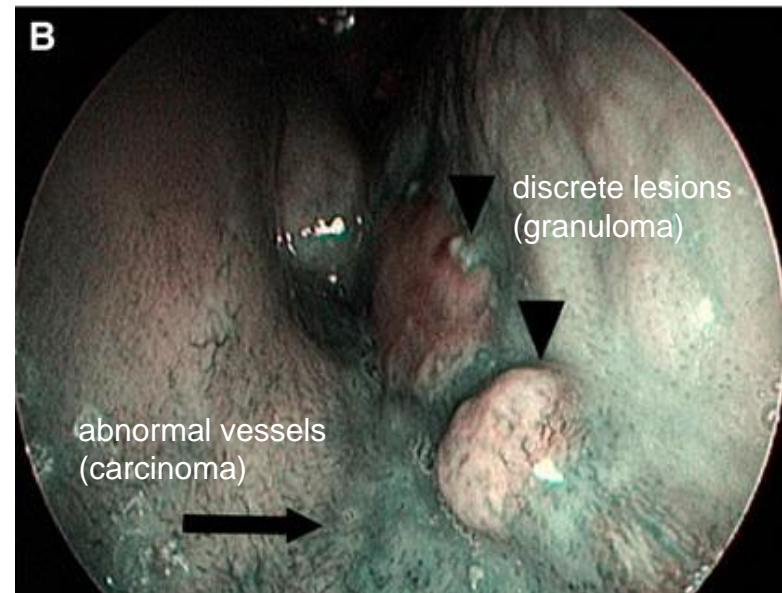
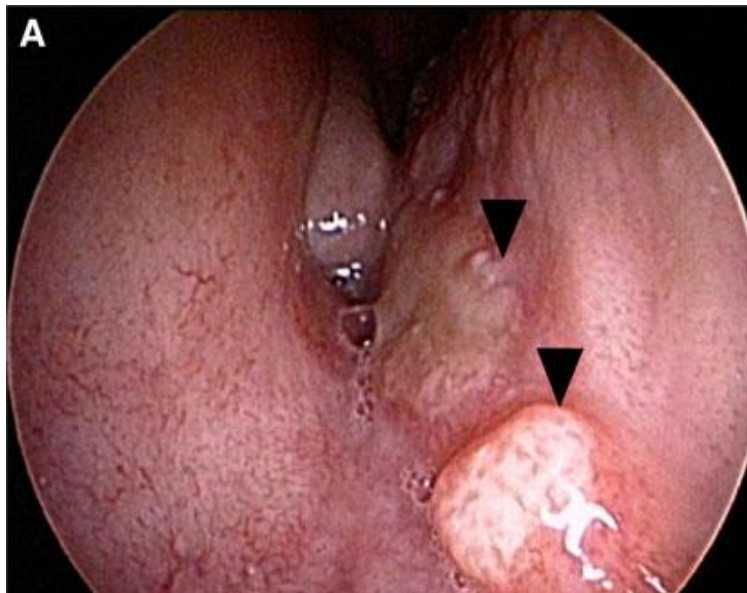


Figure from Cauberg E. 2009



Narrow-Band Imaging (NBI) (2)

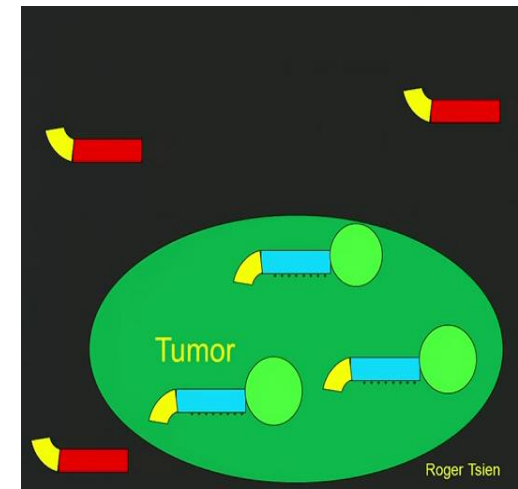
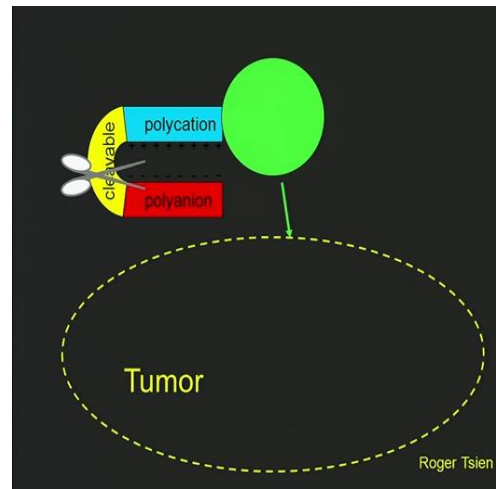
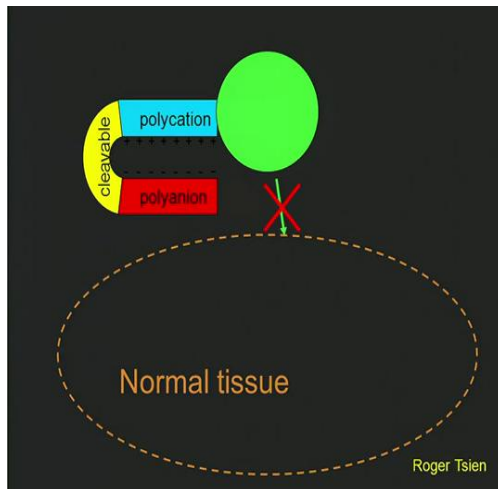
- Specific neoangiogenic patterns → premalignant or neoplastic lesions [Peretti 2011]:
 - darker areas in a context of green-blue normal mucosa;
 - scattered thick dark spots;
 - increased microvascular density;
 - winding vessels (intraepithelial papillary capillary loops);
- Definition of the histopathologic nature of the lesion.



Figures from Peretti G. 2010

Color-Coded Surgery (1)

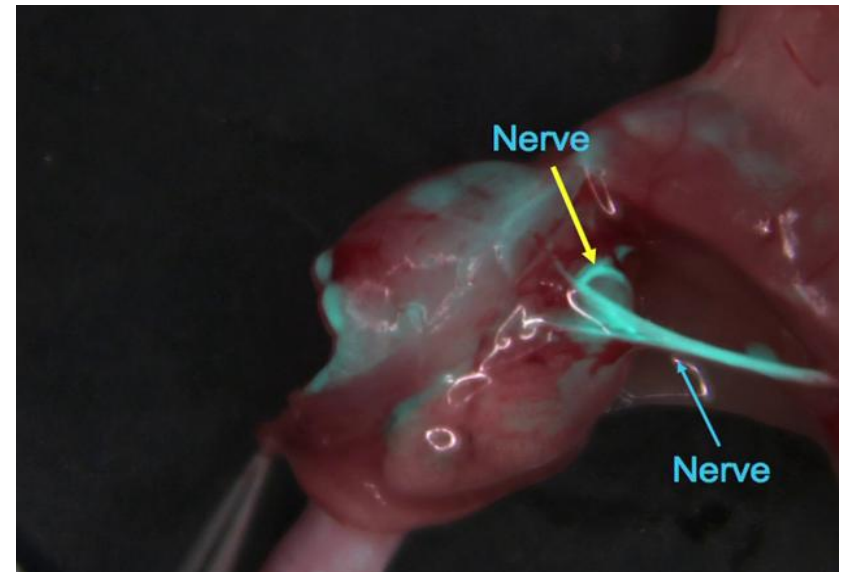
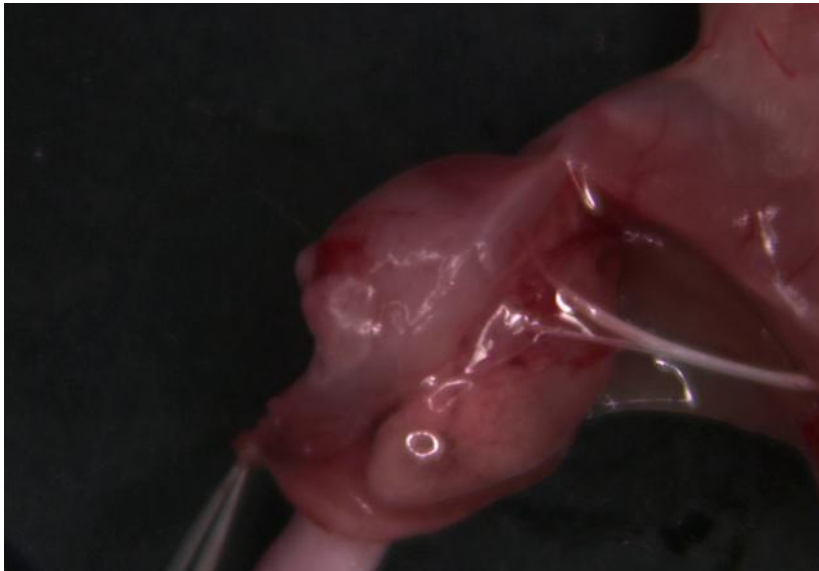- Nguyen Q.T. and Tsien R. [Nguyen Q.T. 2010];
- Visualize tumors during surgery using activable cell-penetrating peptides (ACPPs);
- POLYCATION (very sticky) + DYER + POLYANION (non stick)+ CLEAVABLE PART;
- Molecular scissors (i.e. protease enzymes that tumor makes);
- The tumor labels itself and it gets fluorescent;



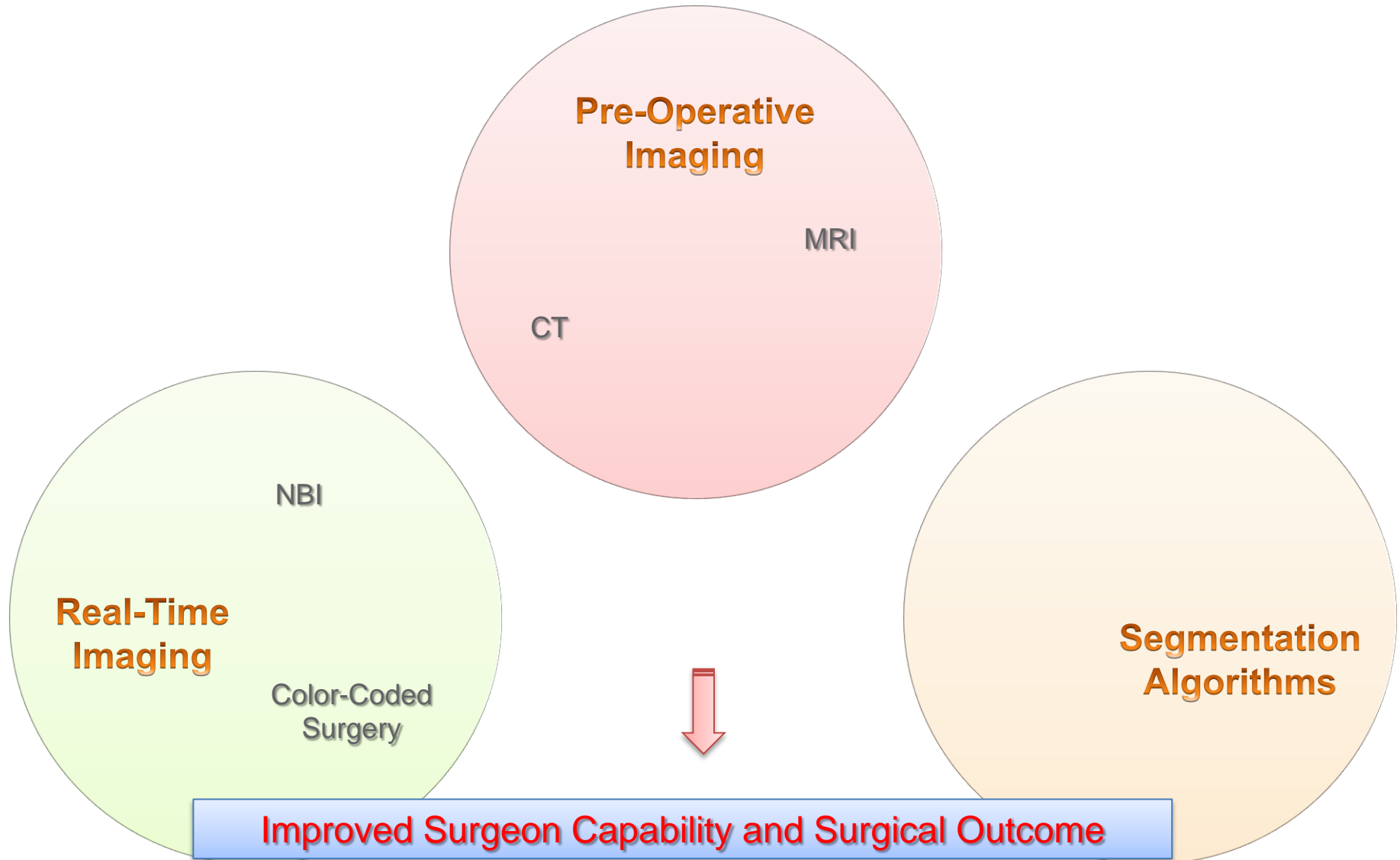
Figures from http://www.ted.com/talks/quyen_nguyen_color_coded_surgery.html

Color-Coded Surgery (2)

- The fluorescent light can go through tissues; this works for metastatic lymph nodes;
- It is visible on a MRI;
- Molecules that were specifically labeling nerves;
- Prepare for eventual human clinical trials.



Figures from http://www.ted.com/talks/quyen_nguyen_color_coded_surgery.html



THANK YOU!

REFERENCES

- [1] Hughes O. R. et al. “Optical and Molecular Techniques to Identify tumor Margins Within the Larynx”, *Head & Neck* - DOI 10.1002/hed November 2010.
- [2] Hermans R. “Head and Neck Cancer Imaging”, Springer 2012.
- [3] Zhou J. et al, “Nasopharyngeal Carcinoma Lesion Segmentation from MR Images by Support Vector Machine”, 3rd IEEE International Symposium on Biomedical Imaging: Nano to Macro, 2006.
- [4] Ritthipravat P. et al. “Automatic Segmentation of Nasopharyngeal Carcinoma from CT Images: Region Growing Based Technique” *IEEE ICSPS 2010*.
- [5] Zaidi H. et al. “Comparative Methods for PET Image Segmentation in Pharyngolaryngeal Squamous Cell Carcinoma”, *Eur J Nucl Med Mol Imaging* (2012) 39:881–891.
- [6] Ingle R., and Kwon K. T., “Automatic segmentation using learning algorithms for high-resolution Magnetic Resonance imaging of the Larynx”, available from: <http://cs229.stanford.edu/proj2009/IngleKwon.pdf>
- [7] Szeto C. et al, “Contact Endoscopy as a Novel Technique in the Detection and Diagnosis of Mucosal Lesions in the Head and Neck: A Brief Review”, *Journal of Oncology*, Volume 2011.
- [8] C. Piazza, F. D. Bon, G. Peretti, and P. Nicolai, “Biologic endoscopy: optimization of upper aerodigestive tract cancer evaluation” *Current Opinion in Otolaryngology & Head and Neck Surgery*, 2011, 19:67-76.
- [9] Q. T. Nguyen, R. Y. Tsien et al. “Surgery with molecular fluorescence imaging using activable cell-penetrating peptides decreases residual cancer and improves survival”, *PNAS*, 2010, vol. 107, n°9.